CASE SPOTLIGHT | Challenging PAE Anatomy: Navigating Severe Pelvic Tortuosity and Achieving Target Embolization

By Zagum Bhatti, MD

PATIENT PRESENTATION

A man in his late 60s presented with severe, progressive lower urinary tract symptoms secondary to benign prostatic hyperplasia. His International Prostate Symptom Score (IPSS) was 26, indicating severely symptomatic disease, with an associated quality of life (QOL) score of 5. Maximum medical therapy, including an α-blocker and a 5-α reductase inhibitor, had failed. Preprocedural ultrasound demonstrated a significantly enlarged vascular prostate gland measuring 120 mL. The patient elected to undergo prostatic artery embolization to achieve symptomatic relief while preserving baseline erectile and ejaculatory function.

PROCEDURAL OVERVIEW

Vascular access was achieved via the right common femoral artery. A flush aortogram showed tortuous bilateral iliac arteries (Figure 1A). A 5-F Carnevale prostate catheter (CPC 15; Merit Medical Systems, Inc.) was used to select the internal iliac arteries.

On the left side, initial angiography suggested a complex type 1 origin of the prostatic artery (Figure 1B), but it was suspected that the prostatic artery could also be arising directly from the anterior division. Rather than attempting to advance the rigid 5-F base catheter deeper into the anterior division (a maneuver that carries a high risk of inducing severe vessel spasm) or converting to an up-and-over long sheath, a 2.5-F, 135-cm Cantata® microcatheter (Cook Medical) was advanced. The microcatheter tip was hand-shaped prior to insertion to precisely match the acute angle of the suspected takeoff. This shapeable tip allowed for catheterization of the prostatic artery by subtly torqueing and hooking the origin of the vessel. Because the Cantata supports high flow rates despite its low outer profile, high-quality digital subtraction angiography (DSA) runs were performed directly through the microcatheter (Figure 1C). This allowed for visualization of the prostatic artery origin while keeping the base catheter safely proximal. The shaped tip then guided the catheter smoothly through multiple acute, consecutive loops into the distal segment of the vessel, where embolization could be performed safely (Figure 1D).

On the right side, a different anatomic challenge was encountered. A prominent, nontarget rectal branch was identified, arising directly from the distal prostatic artery (Figure 1E). While this anatomy often forces operators to downsize to a 2-F catheter or deploy microcoils to protect the rectum, the 2.5-F Cantata exhibited trackability.

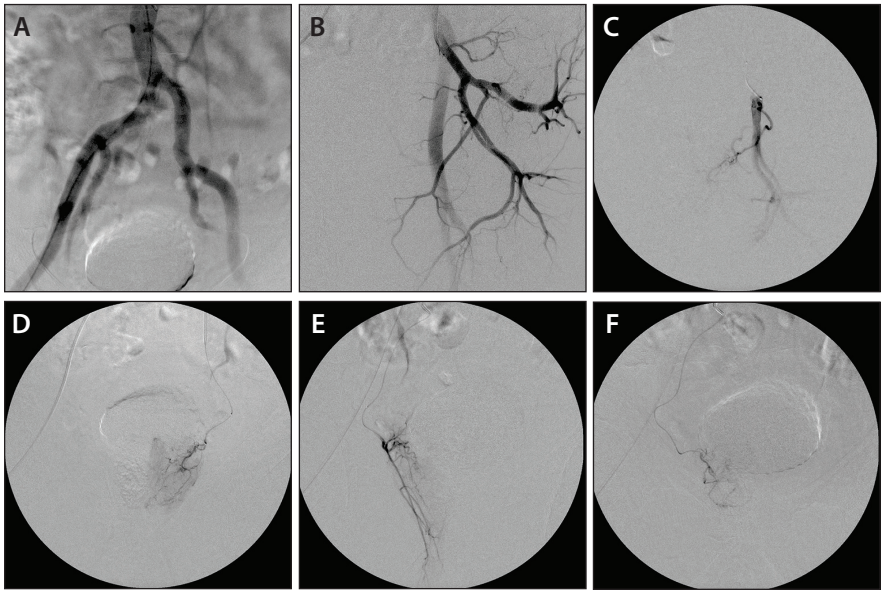

Figure 1. Flush aortography demonstrating tortuous bilateral iliac arteries (A). Initial left-sided angiography showing the suspected prostatic artery origin (B). DSA through the Cantata microcatheter visualizing the prostatic artery origin (C), followed by distal catheterization through tortuous anatomy (D). Right-sided angiography demonstrating a rectal branch arising from the distal prostatic artery (E). Subselective catheterization beyond the rectal branch for safe embolization without coiling (F).

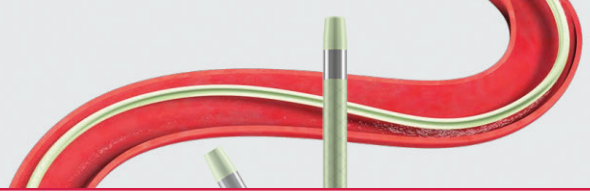

Paired with a 0.016-inch-diameter wire guide, it bypassed the rectal takeoff, tracking subselectively beyond the branch into a secure embolization position, eliminating the need for coiling (Figure 1F).

The embolic regimen consisted of 100–300-µm calibrated microspheres, followed by a customized gelatin sponge slurry to achieve complete stasis. Despite the winding anatomy and the viscosity of the gelatin sponge mixture, the Cantata's large inner diameter allowed for smooth, continuous delivery with no catheter clogging.

OUTCOME AND FOLLOW-UP

At 3-month clinical follow-up, the patient reported dramatic symptomatic improvement. His IPSS score decreased from 26 to 9, and his QOL score improved from 5 to 1. Follow-up imaging demonstrated a 33% reduction in total prostate volume (80 mL), with no adverse events, nontarget embolization, or sexual dysfunction reported.

PHYSICIAN DISCUSSION

This case illustrates that you don't always need to sacrifice inner lumen size and pushability by downsizing to a 2-F catheter when facing extreme pelvic tortuosity or delicate anatomy. The 2.5-F Cantata microcatheter bridges the gap in part due to its hand-shapable tip.

On the left side, the ability to shape the Cantata tip provided the precise steering needed to hook a tricky anterior division origin. Combined with the catheter's high flow rates, the anatomy was mapped via microinjections without risking vessel spasm with a larger base catheter. On the right, the shaped tip allowed deliberate steering past a prominent rectal branch, saving the time and cost of deploying protective coils.

Furthermore, even when curved through these tight configurations, the internal lumen maintains its integrity. Injecting a gelatin sponge slurry can easily clog other catheters in tortuous anatomy, but the Cantata handled the slurry smoothly. ■

IR-WF1283068-EN-F